

Implementing Tomosynthesis Into Your Practice

Stamatia Destounis, MD, FACR, FSBI

Current State of Digital Breast Tomosynthesis (DBT) implementation

- Early adaptation into routine clinical practice
 - Practices need to develop imaging workflow protocols if they do not convert 100% of their existing units to DBT
-

DBT TECHNOLOGY

- Several manufacturers are developing DBT
 - Have applied different methods to develop and perform tomosynthesis
- Manufacturers vary:
 - Arc of movement (typically 11-60°)
 - Number of individual exposures (typically 9-25)
 - Continuous or pulsed exposure
 - Stability or movement of the detector
 - Exposure parameters
 - Total dose
 - Effective size of pixels
 - X-ray source/filter source
 - Single or binned pixels
 - Patient position

Tomosynthesis Research

Author	Year
Friedewald et al.	2014
Skaane, et al.	2013
Brandt, et al.	2013
Rose, et al.	2013

Friedewald, et al. 2014

- Evaluated performance of digital mammography (DM) alone and DM in combination with DBT
- Retrospective analysis of 13 breast centers (some 100% and some hybrid conversions)
- 454,850 total exams were performed

Friedewald, et al. 2014

Modality	Recall rate (per 1000)	Biopsy rate (per 1000)	Cancer detection rate (per 1000)	Invasive detection rate (per 1000)	DCIS detection rate (per 1000)	Recall Mean PPV	Biopsy Mean PPV
FFDM alone	107	18.1	4.2	2.9	1.4	4.3%	24.2%
FFDM + DBT	91	19.3	5.4	4.1	1.4	6.4%	29.2%

*Additional increases included increase in detection rates for IDC and ILC with DBT added

The addition of DBT resulted in a decrease in recall rates and an increase of cancer detection

Study Summary

- Decrease in recall rate of -16 with DM + DBT
- Increase in biopsy rate for DM + DBT of 1.3
- Increase in cancer detection rate of 1.2 with DM + DBT
- Increase in invasive cancer detection of 1.2 with DM + DBT
- No difference in detection rate of DCIS
- Increase in PPV for recall of 2.1% with DM + DBT
- Increase in PPV for biopsy of 5.0% with DM + DBT

11/13 sites increased cancer detection and decreased recall rates with the addition of DBT

2 sites experienced increase in recall rate with DBT had either short duration of implementation or low volume of exams per radiologist

Skaane, et al. 2013

- Prospectively assessed:
 - Cancer detection rates
 - False positive rates before arbitration
 - Positive predictive values for women recalled after arbitration

Skaane, et al. 2013

- Evaluated DM plus DBT in screening program
 - Detection rates for invasive and in situ cancers
 - 6.1 per 1,000 for DM alone
 - 8 per 1,000 for DM plus DBT
 - FP rates before arbitration
 - 61.1 per 1,000 with DM alone
 - 53.1 per 1,000 with DM and DBT
 - After arbitration, PPVs for recalled patients with cancers verified later was 29.1% and 28.5% respectively
- DM plus DBT in screening resulted in a significantly higher cancer detection rate and enabled detection of more invasive cancers

Brandt, et al. 2013

- Evaluated DBT as an alternative to conventional diagnostic mammography views in the workup of non-calcified findings recalled from screening
 - Results suggest DBT can replace conventional diagnostic views while achieving similar sensitivity and specificity
 - 2 view DBT was adequate evaluation in more than 90% of findings
 - Minimal change in the use of ultrasound

Rose, et al. 2013

- Compared performance measures after the introduction of screening DBT in a clinical practice
 - Compared recall rates, biopsy rates, cancer detection rates, and PPVs for 6 radiologists
 - 13,856 studies without DBT
 - 9,499 with DBT

Rose, et al. 2013

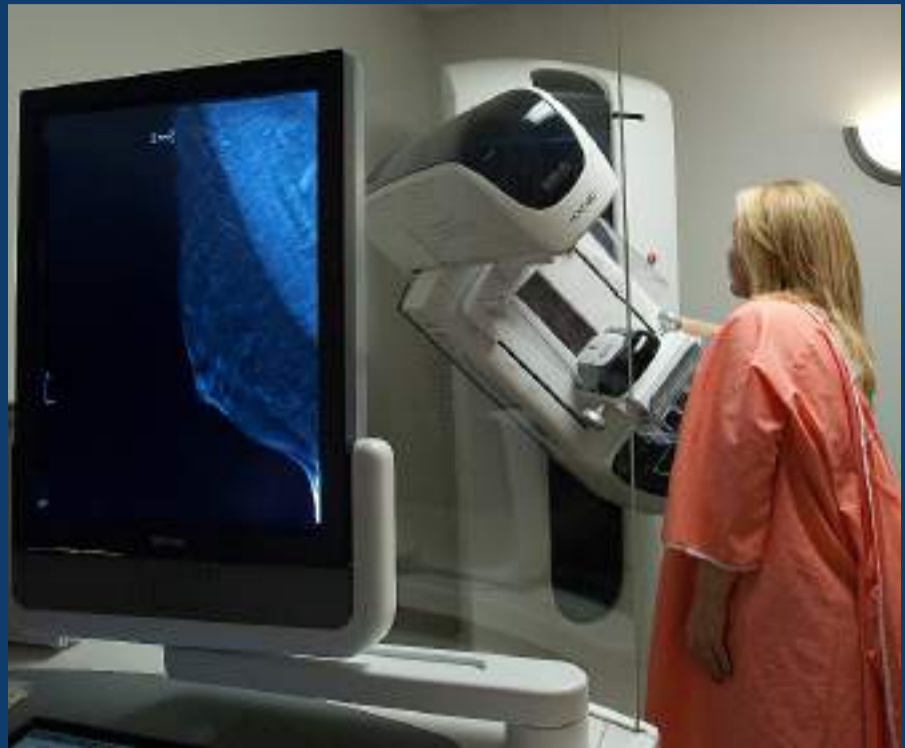- Recall rate drop: 8.7% to 5.5%
 - Biopsy rate change: 15.2 biopsies per 1,000 screenings without DBT to 13.5 with DBT
 - PPV 26.5% without DBT, 39.8% with DBT
 - Cancer detection rate: 4.04/1,000 without DBT and 5.4/1,000 with DBT
 - Invasive cancer detection rate: 2.8/1,000 without DBT and 4.3 with DBT
 - PPV increase for recalls: 4.7% without DBT to 10.1% with DBT
- DBT reduced recall and increased cancer detection
-

DBT RESEARCH SUMMARY

- DBT reduces recall rates
- DBT increases cancer detection rates
- DBT is useful as a diagnostic tool

IMPLEMENTATION CONSIDERATIONS

- Costs
- Room requirements
- PACS/Bandwidth
- Training
- Education: patient, referring physicians/ health care professionals
- Biopsy capabilities for DBT only findings
- Implementing Synthetic views
- CAD



COSTS

- More expensive than a 2D full field digital mammography unit by as much as 50%

ROOM REQUIREMENTS

- 12 x 12 feet minimum; DBT room size requirement is slightly larger than size required for FFDM
 - Vendor will assist with room design/set up
 - Existing room space may need to be altered to house DBT unit (increasing implementation cost)
-

DBT STUDIES/PACS/BANDWIDTH

- PACS
 - Third party workstation
- Image display
- Storage
- File size
- Image display

DBT IMAGE DISPLAY

- Workstation requirements
 - Simply has the ability to display FFDM (in accordance with IHE Profile)
- Consult with your PACS vendor regarding memory/monitors/video cards for quality DBT display

STORAGE: FACTORS TO CONSIDER

- Size of files
- Volume of patients undergoing DBT imaging
- Radiologist reading workflow
 - Number of priors needed
 - Remote Reading
 - This will impact bandwidth needed

FILE SIZE

- 4-view DBT exam is about 20 times the size of 2D
 - 2D = approx. 180 MB
 - Compressed = approx. 60 MB
 - Compresses approx. 3 to 1
 - Combo DBT = approx. 2 GB
 - Compressed = approx. 200 MB
 - Can compress tomo images approx. 10 to 1
 - Required storage dramatically increases
-

DBT STORAGE REQUIREMENTS

- Storage from 2/2014- 2/2015
 - 6 TB of DBT studies
 - 4.5 TB of 2D studies
 - Note: Includes raw images
- We did approximately 4 x's as many 2D studies in comparison to DBT studies, but DBT accounted for 1.5 TB more in storage

WHICH IMAGES DO YOU STORE?

- We store only the reconstructed images
 - Projection images
 - These images are not DICOM compatible
 - They are in proprietary format
 - May be helpful for motion
 - PACS unable to display as they are in proprietary format
-

TRAINING/LEARNING CURVE

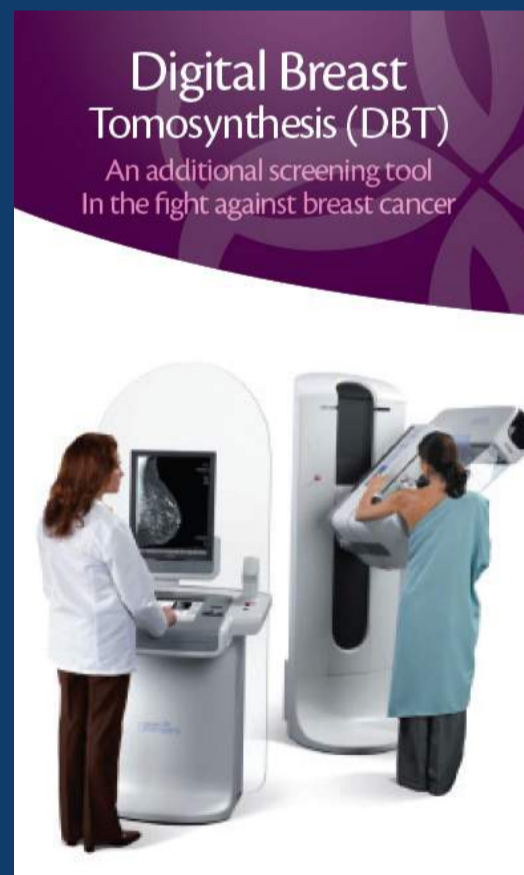
- Radiologist
 - Document 8 hour of training course with test cases
- Image interpretation
 - Reading time: 2 to 3 times longer than DM (initially 5-10 minutes), with experience: ~ 2 minutes
- Technologists
 - Document training through applications specialist or designated staff
 - Learning curve with equipment (more computerized than traditional units)
 - Motion: big concern

SKAANE, ET AL.

- Average interpretation time for DM:
 - 42.3 seconds
 - Average interpretation times for DM plus DBT:
 - 84.5 seconds during first 200 cases
 - 59.7 seconds during last 200 cases, respectively
 - Trend toward shorter reading times with increasing experience
 - DBT time remained approximately 40% longer than DM
-

PATIENT EDUCATION

- Press release
- Patient brochures
- Website



BIOPSY CAPABILITES

DBT found/predominant findings

- DBT biopsy capability: Yes/No
 - Yes
 - DBT guided biopsy
 - No
 - Thorough Ultrasound evaluation
 - Ultrasound biopsy
 - Additional FFDM imaging

SCHRADING, ET AL.

Prospectively compared the clinical performance of DBT guided VAB to prone stereotactic biopsy in 216 lesions

165 Stereo VAB

- 93.3% (154) success rate
 - 11 unsuccessful
 - 9 inaccessible
 - 2 failed retrieval of Ca++
- 100% rad/path concordance
- 4 upgrades
 - 2 atypia to DCIS
 - 2 DCIS to invasive

51 DBT VAB

- 100% success rate
- 100% rad/path concordance
- No upgrades

CAD & SYNTHETIC VIEWS

SKAANE, ET AL. 2013 RESEARCH

- Compared the diagnostic performance of combined FFDM plus DBT with synthesized 2D plus DBT
- 8 radiologists prospectively interpreted 2 different periods of mammograms independently
 - Period 1 – Initial version of C-View (1/22/2010 to 12/21/2011)
 - Period 2 – Current version of C-View (1/20/2012 to 12/19/2012)
- Used a 5-point rating scale for probability of cancer for interpretation


The combination of the current version of reconstructed 2D images (period 2) and DBT performed comparably to FFDM plus DBT in terms of cancer detection rates and false positive scores

SYNTHESIZED 2D

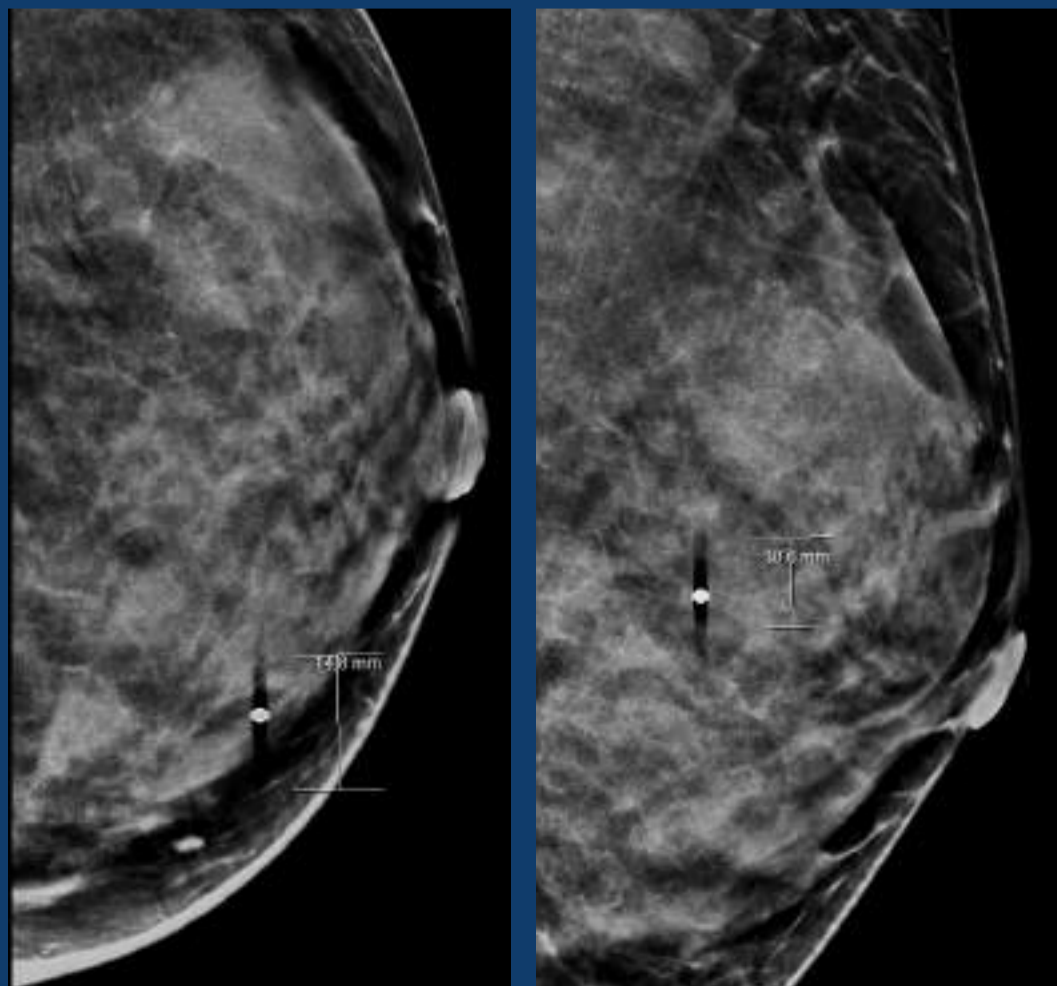
- Reduced dose when only acquiring the DBT scan
- Enables
 - Overview of architecture/asymmetry
 - Comparison to 2D Priors
 - Visualization of calcifications that may be overlooked on slices

C-VIEW SYNTHESIZED 2D IMAGE

- How does it work?
 - Perform a standard tomosynthesis scan (existing system)
 - Reconstruct tomosynthesis slices (existing system)
 - Synthesize 2D image (C-View)
 - Similar to Maximum Intensity Projection (MIP) as done with MRI images



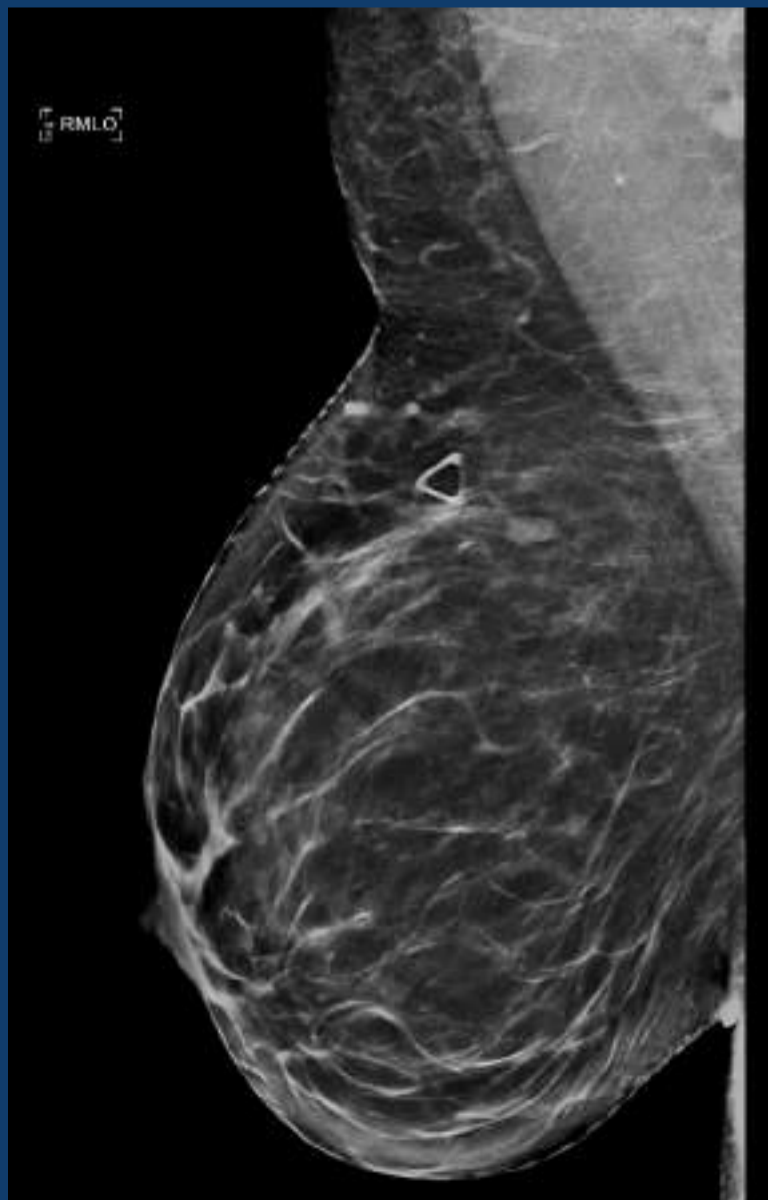
C-VIEW SYNTHESIZED 2D IMAGE



ARTIFACT WORK-AROUND

- Check projection images
 - Pitfall occurs when a 3rd party PACS vendor is used: projection images are not sent to PACS and only visible at acquisition
- Use different kind of markers
 - Plastic base

ARTIFACT WORK-AROUND



Marker in patient's area of concern on synthetic view

IMPLEMENTATION

- Hybrid Conversion
 - Who do you offer DBT exam to?
 - Tissue type
 - Personal history of breast cancer
 - High risk
 - Baseline/Age
 - Patient request
 - Diagnostic: radiologist request
-

DBT IMPLEMENTATION

- Billing considerations
 - ACR Guidance Statement
 - Screening DBT - 77063, Screening digital breast tomosynthesis, bilateral
 - Diagnostic DBT- G0279, Diagnostic digital breast tomosynthesis unilateral or bilateral

IMAGE COMPARISON

- Comparing 2D and DBT in a hybrid transition
 - Compare this year's DBT to last year's 2D?
 - If patient had DBT this year, will we route the patient to DBT next year?
 - Compare DBT to DBT?
-

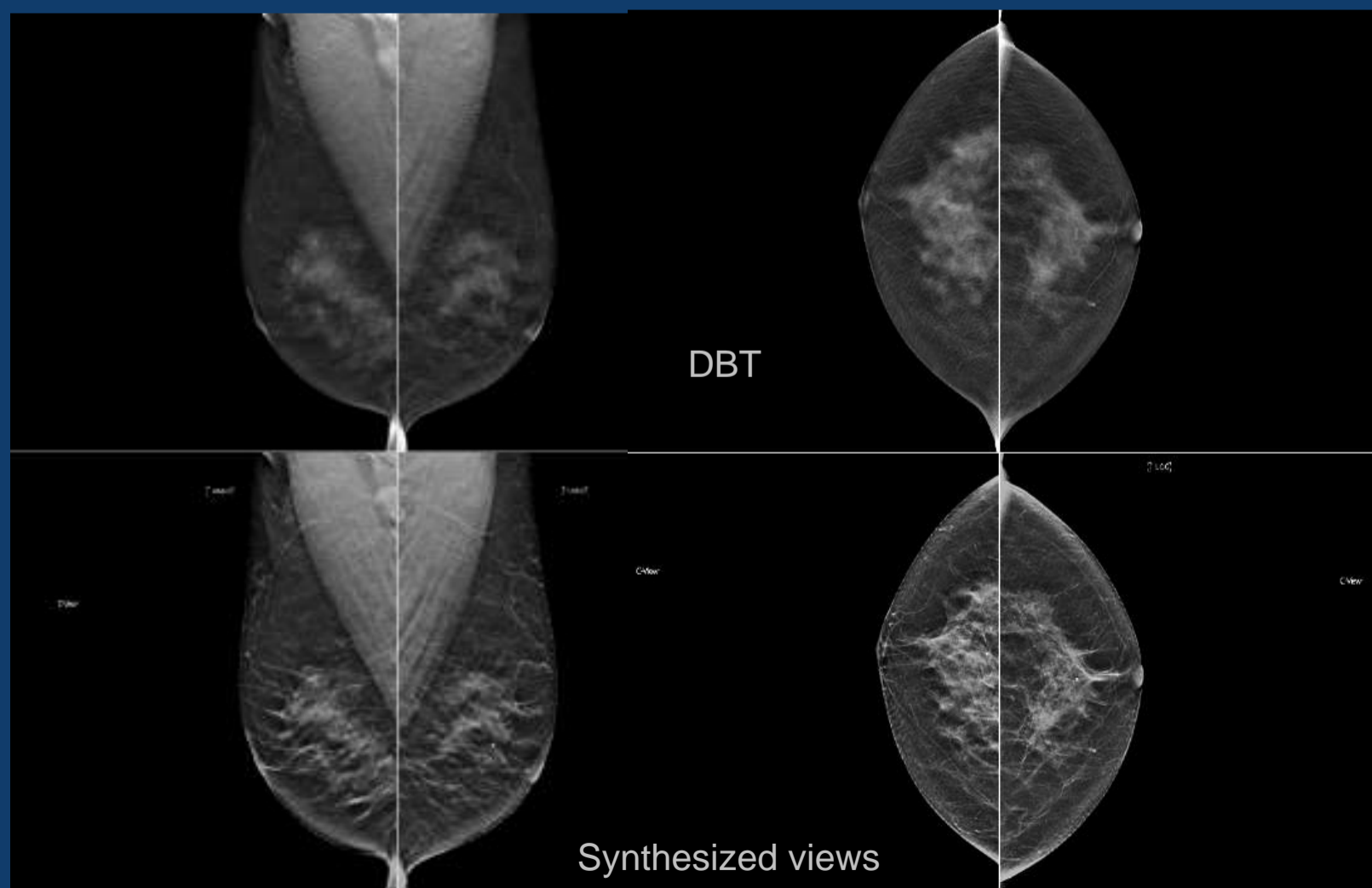
HANGING PROTOCOLS

- Have a consensus hanging protocol in a multi-radiologist practice
 - It is helpful to reach a hanging protocol similar to 2D
 - It will become a formidable task to read multiple DBT hangings
- Our preference has been to review 2D and then pull up DBT with each 2D image side-by-side

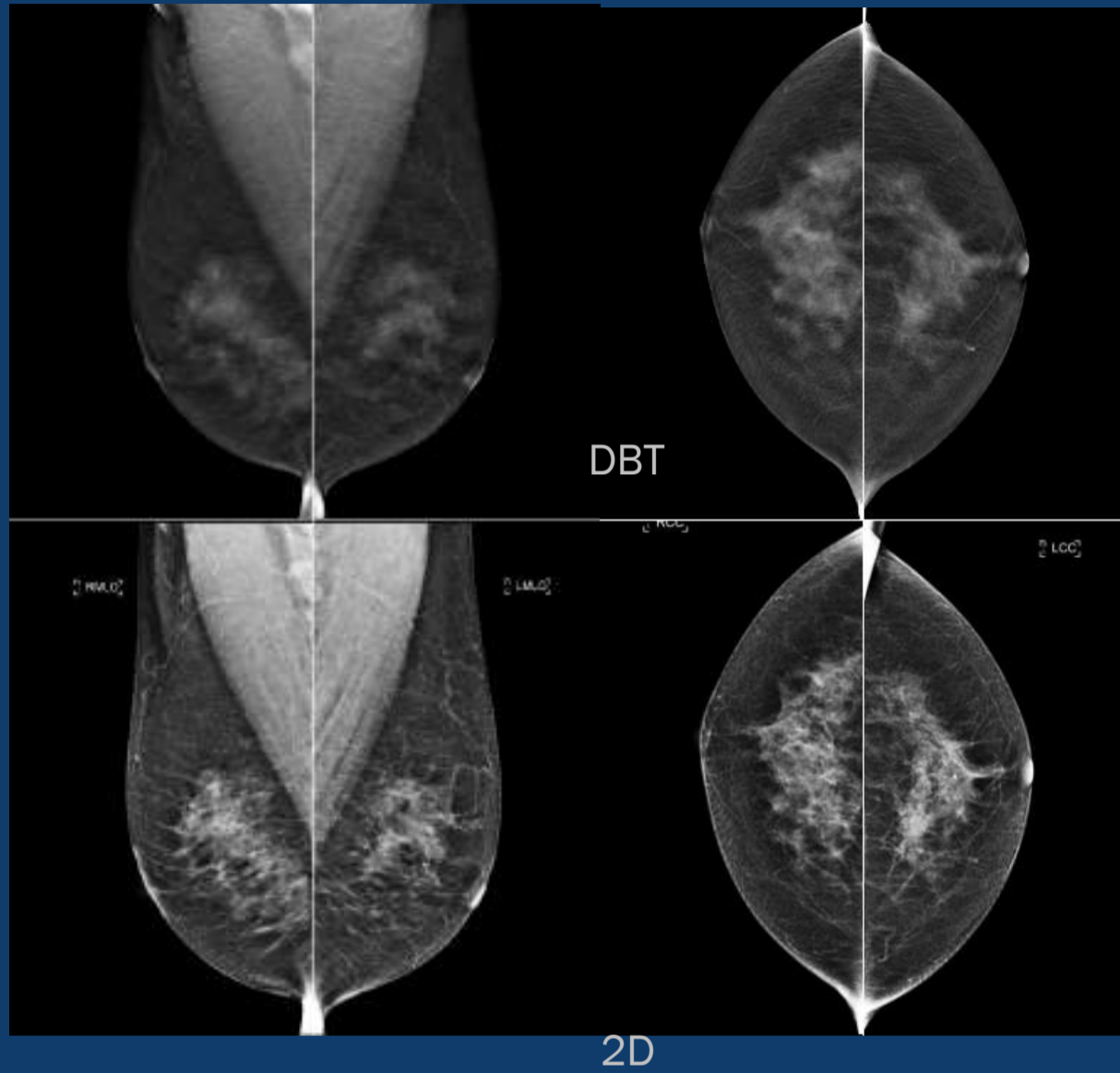
HANGING PROTOCOLS

- With the implementation of DBT, several more hanging protocols were created
- View:
 - 2D and DBT current (MLO and CC projections)
 - 2D current and 2D prior
 - Follow routine 2D protocol
 - At the end added 2D RMLO v. DBT RMLO, 2D RCC v. DBT RCC, etc.

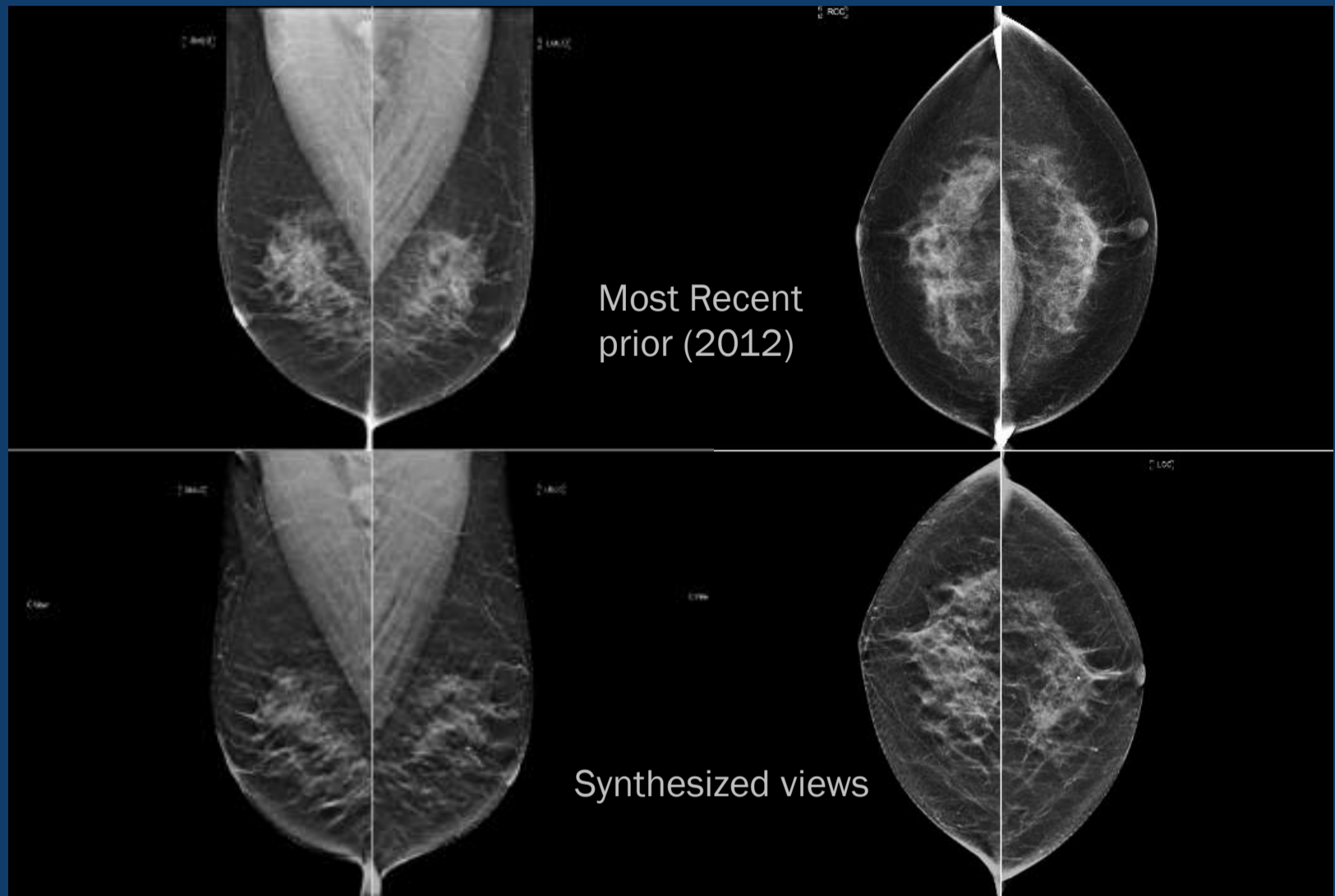
HANGING 1ST UP



HANGING 2ND UP



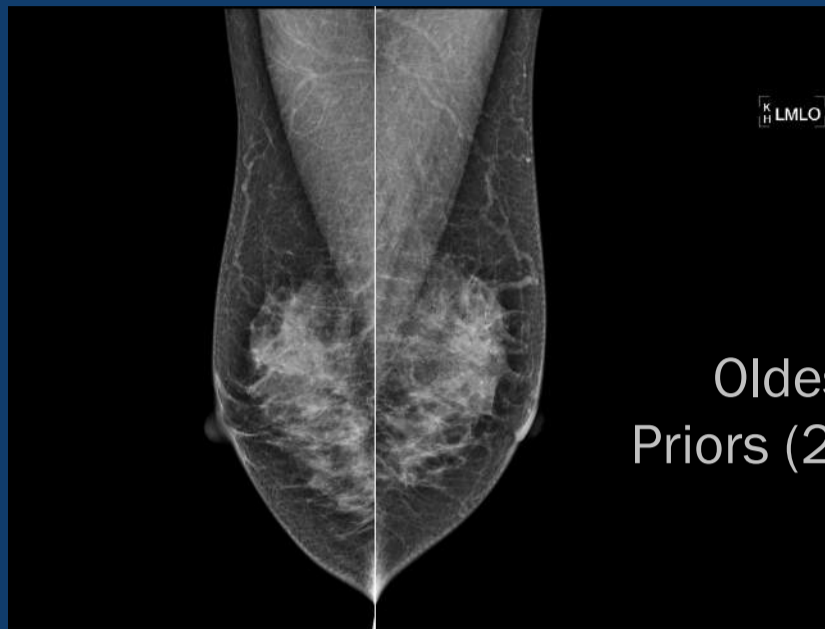HANGING 2ND UP



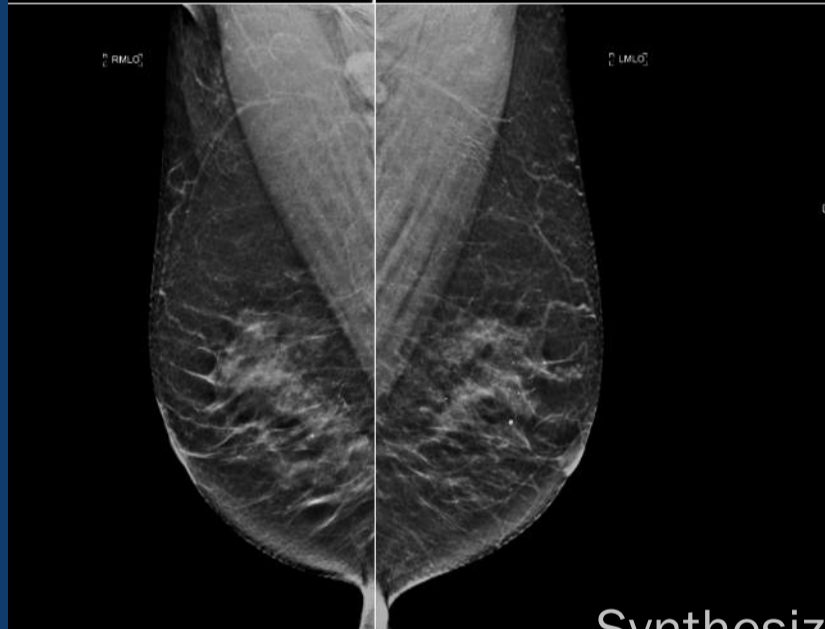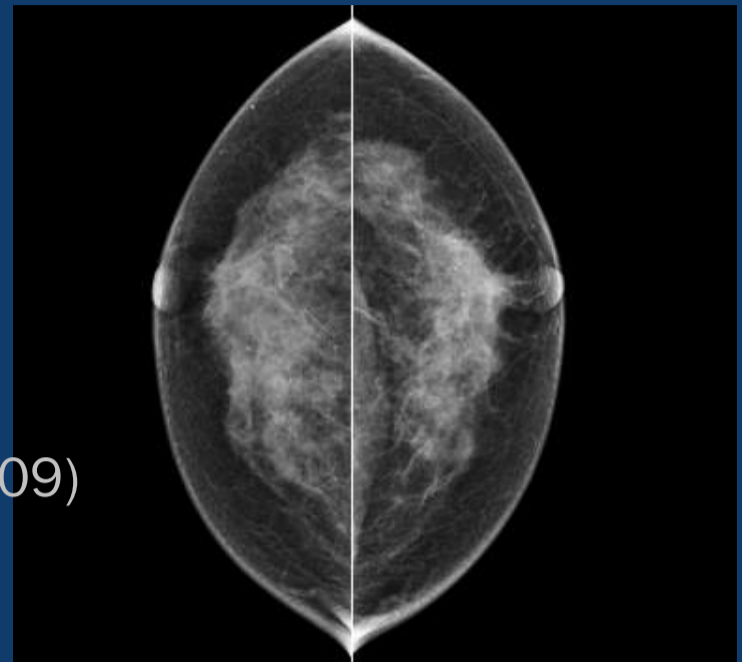
Most Recent
prior (2012)

Synthesized views

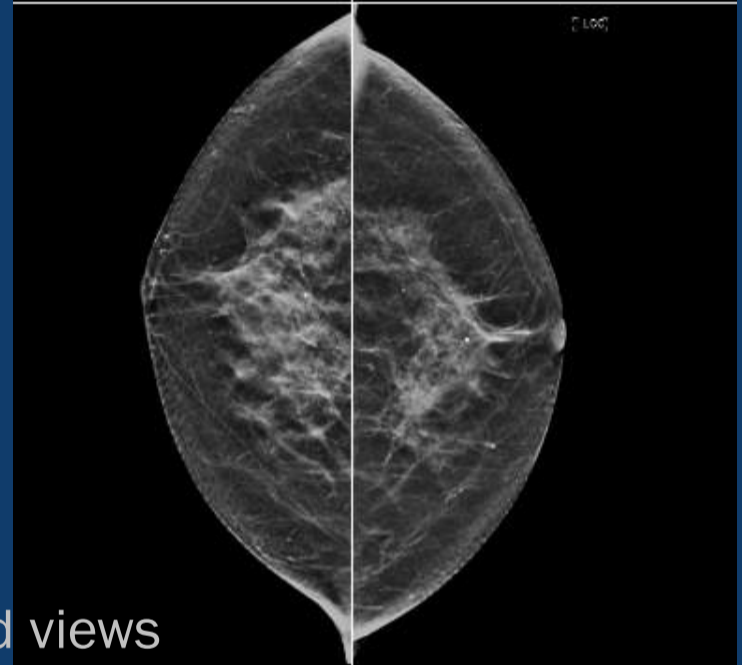HANGING 2ND UP



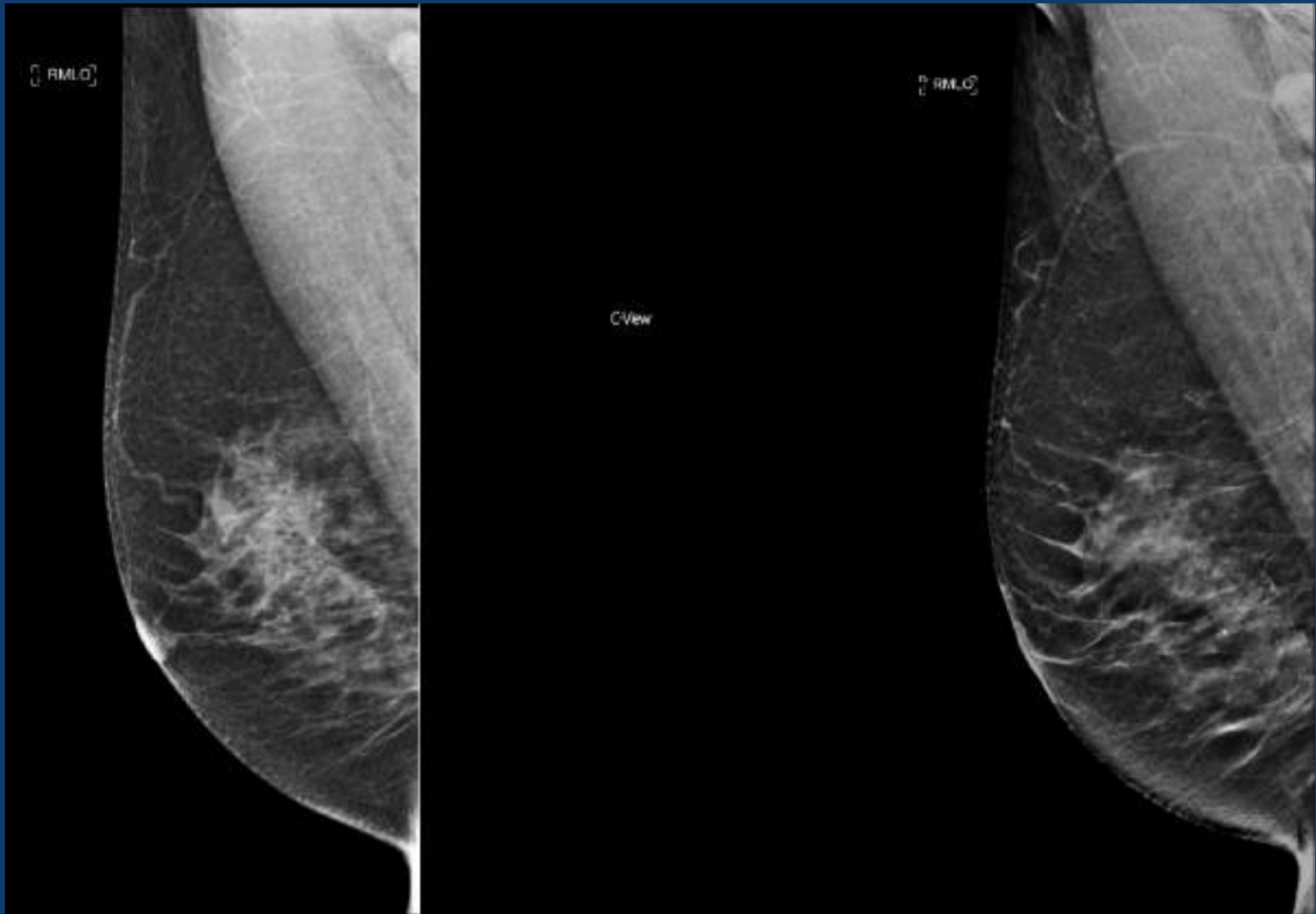
Oldest
Priors (2009)



Synthesized views



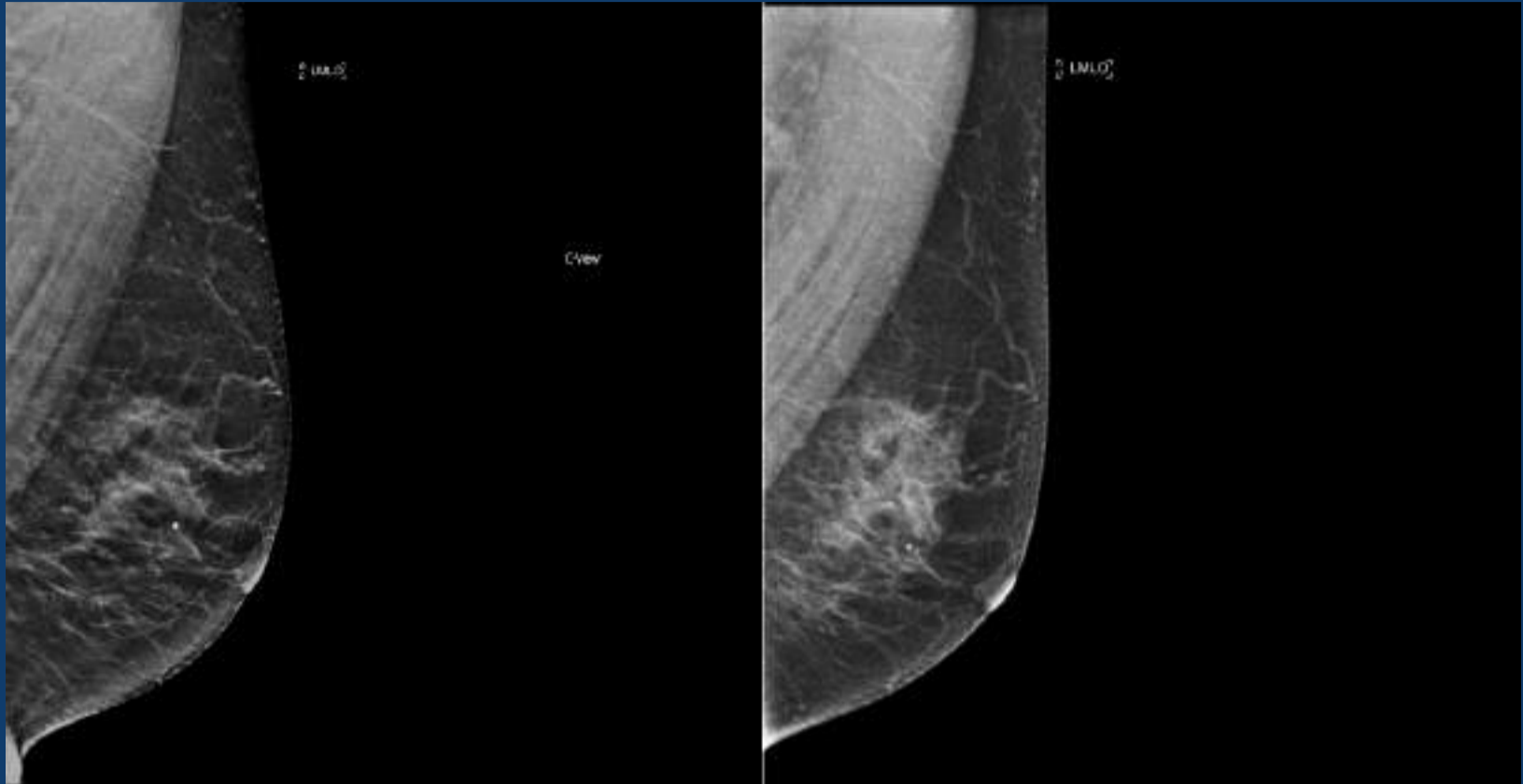HANGING 2ND UP



Recent prior (2012)

Synthetic view

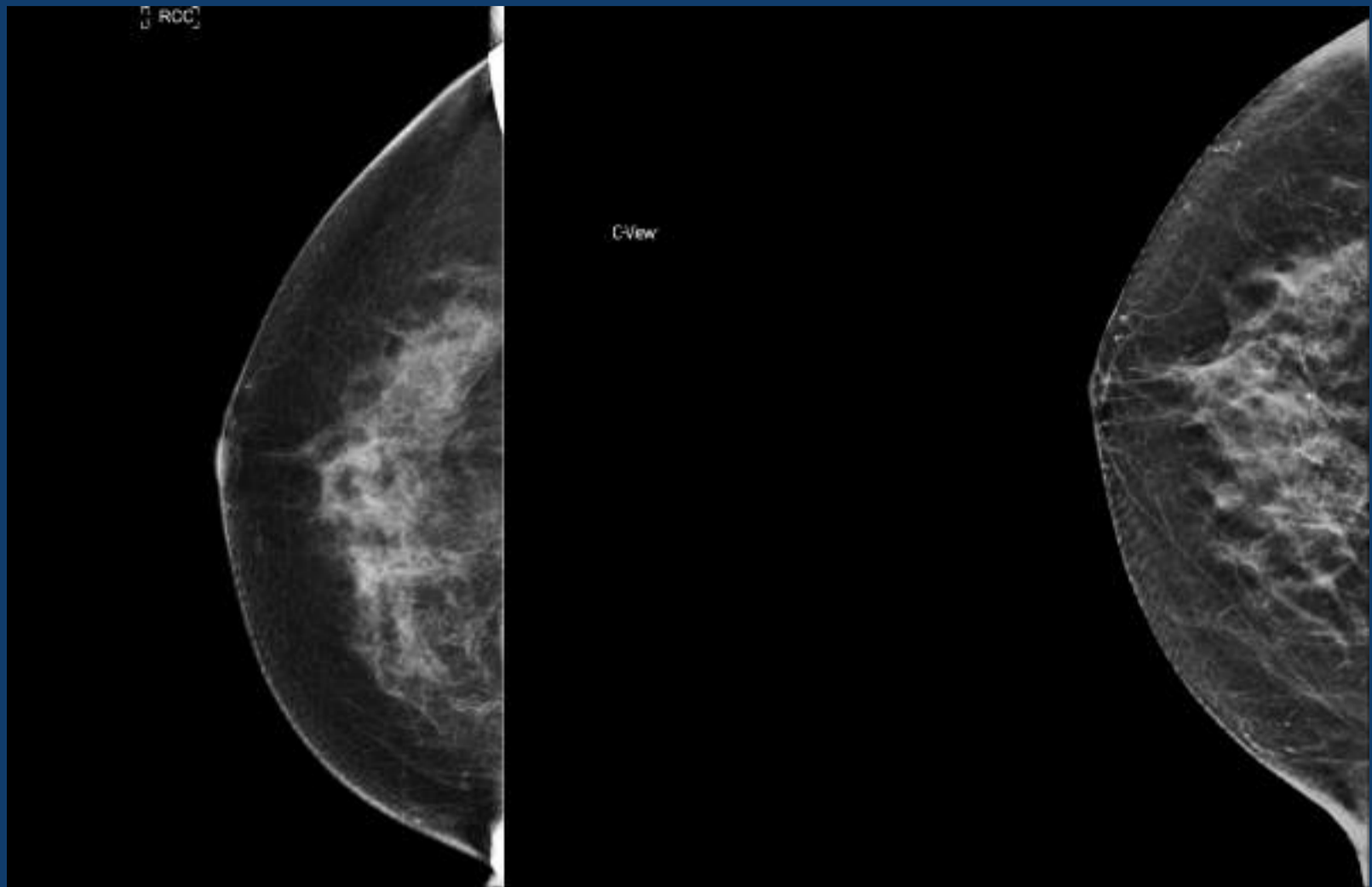
HANGING 2ND UP



Synthetic view

Recent prior (2012)

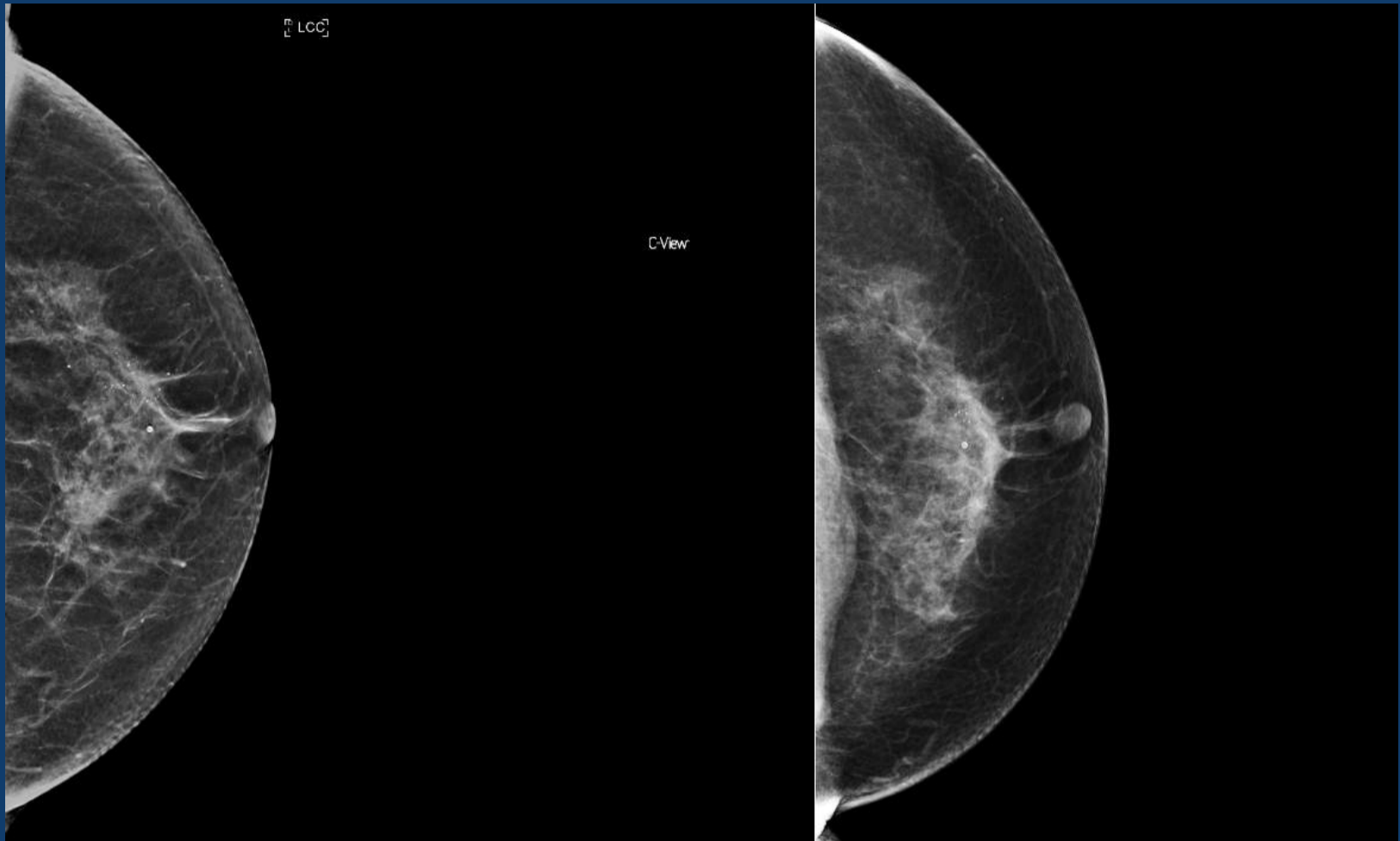HANGING 2ND UP



Recent prior (2012)

Synthetic view

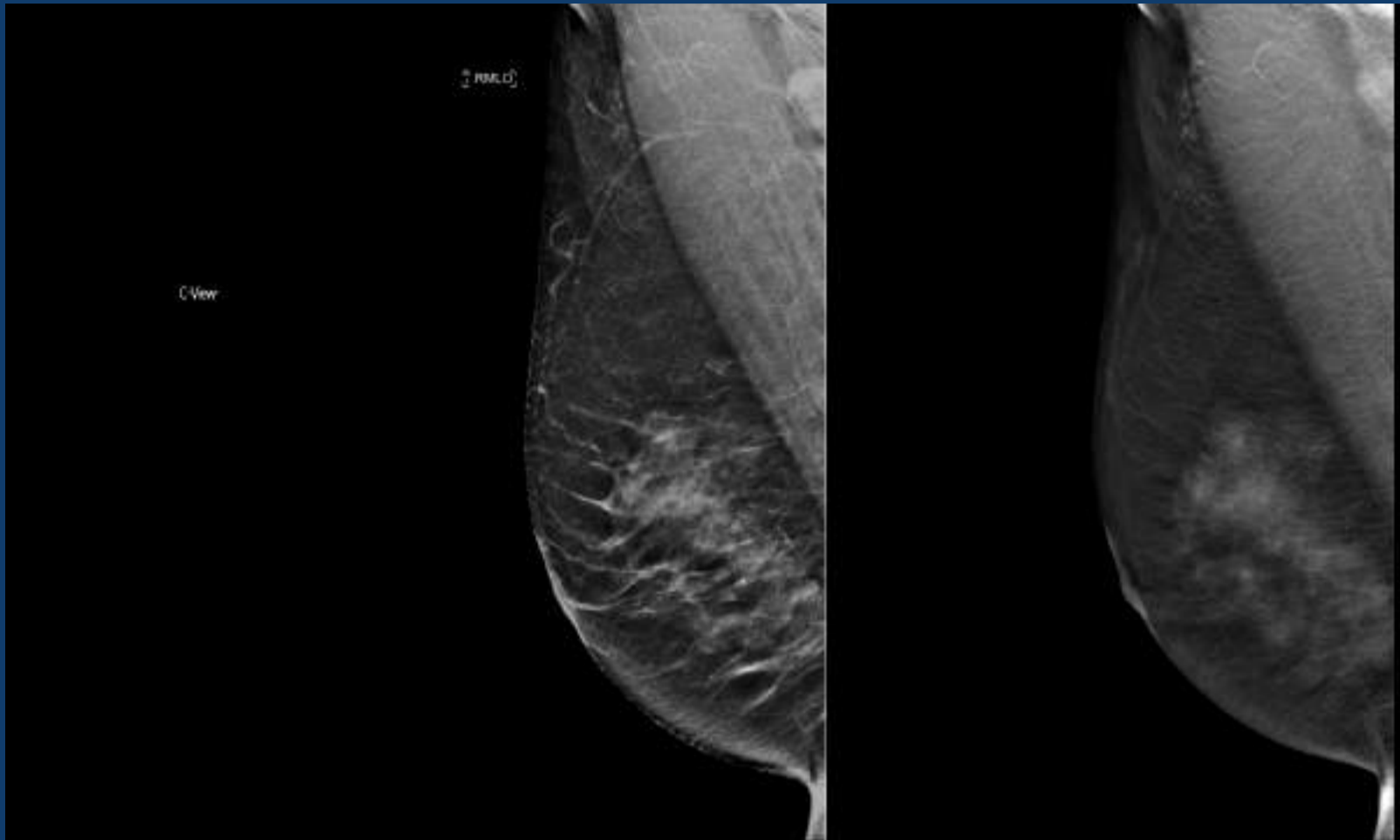
HANGING 2ND UP



Synthetic view

Recent prior (2012)

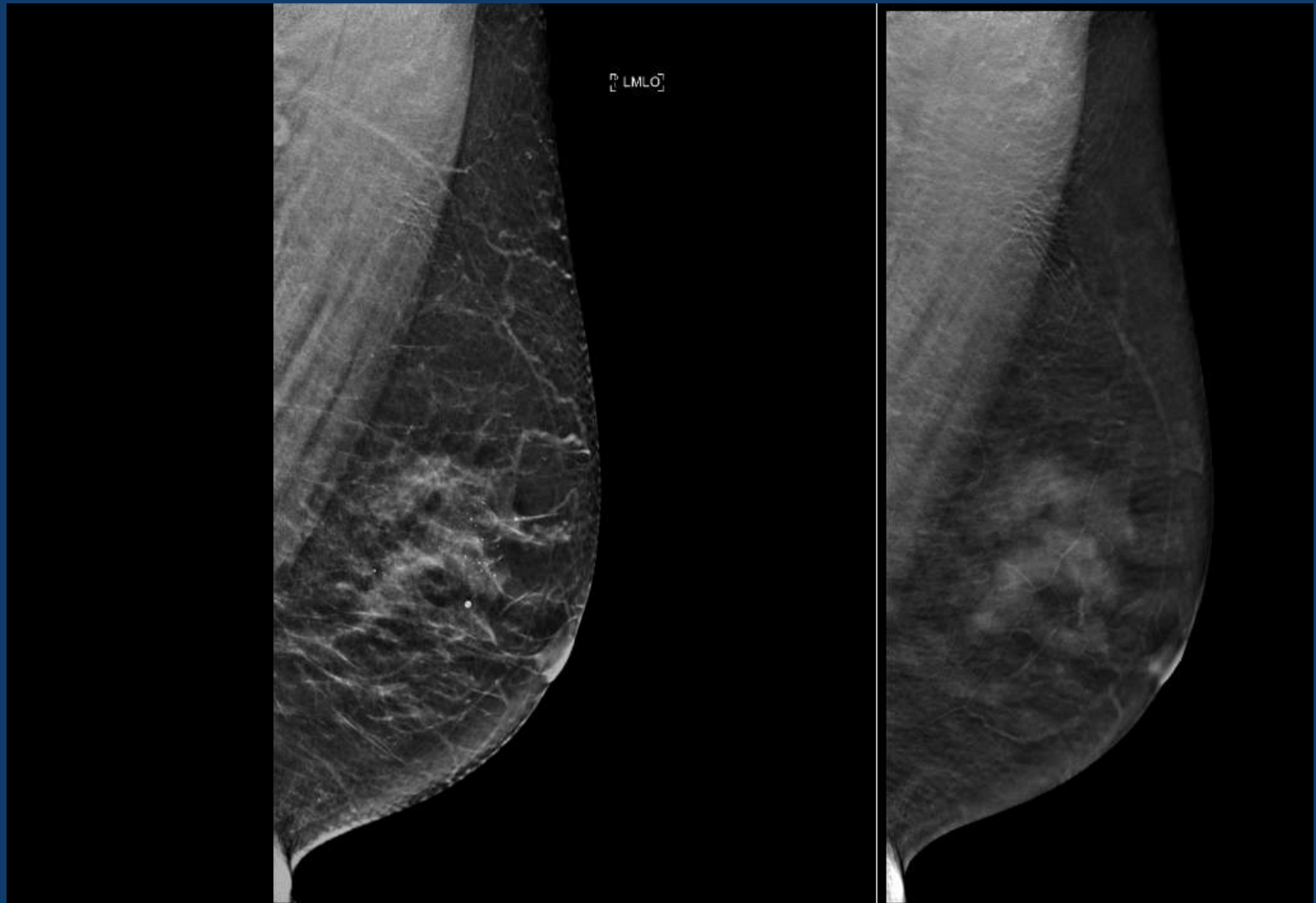
HANGING 2ND UP



Synthetic view

DBT

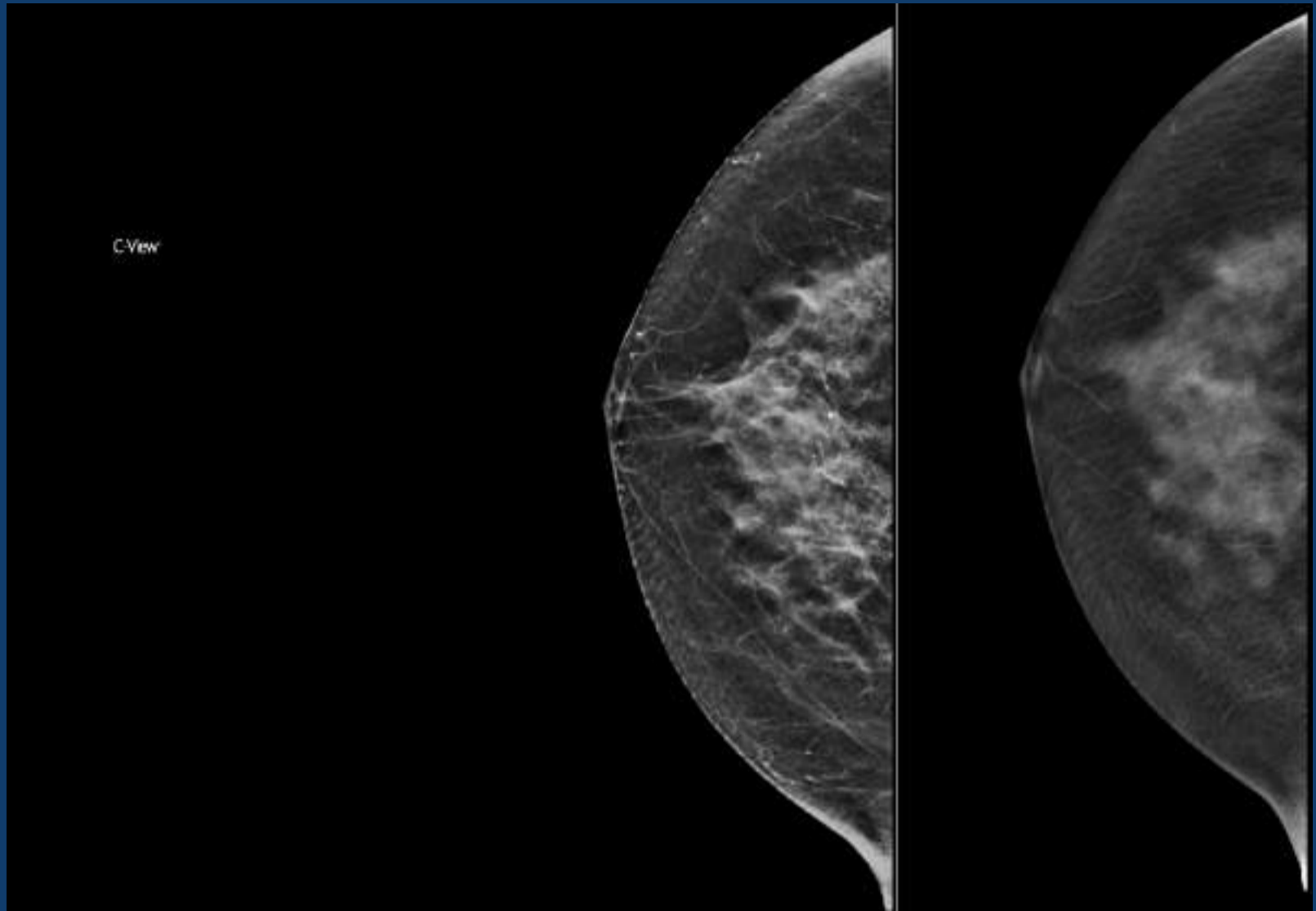
HANGING 2ND UP



Synthetic view

DBT

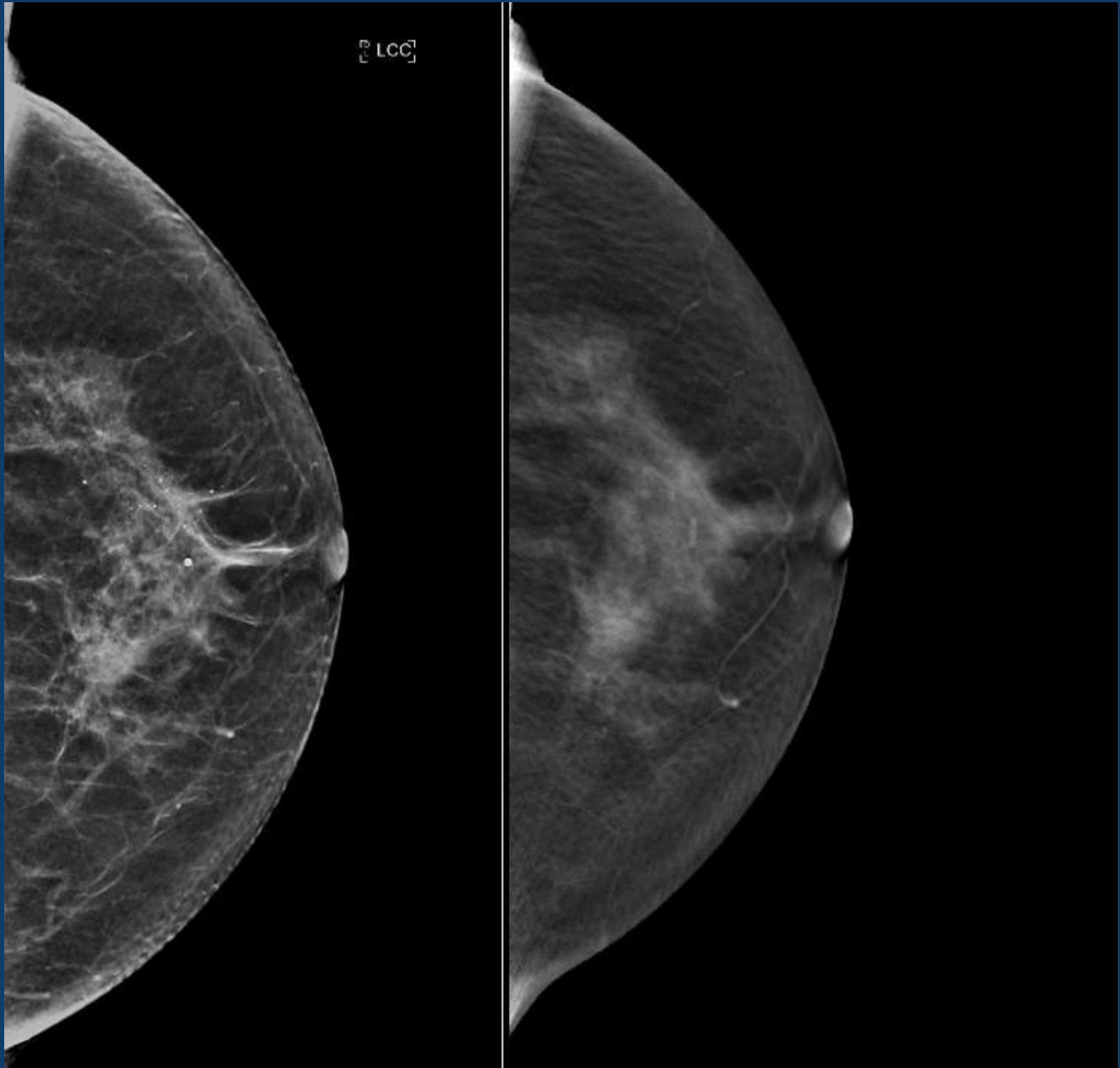
HANGING 2ND UP



Synthetic view

DBT

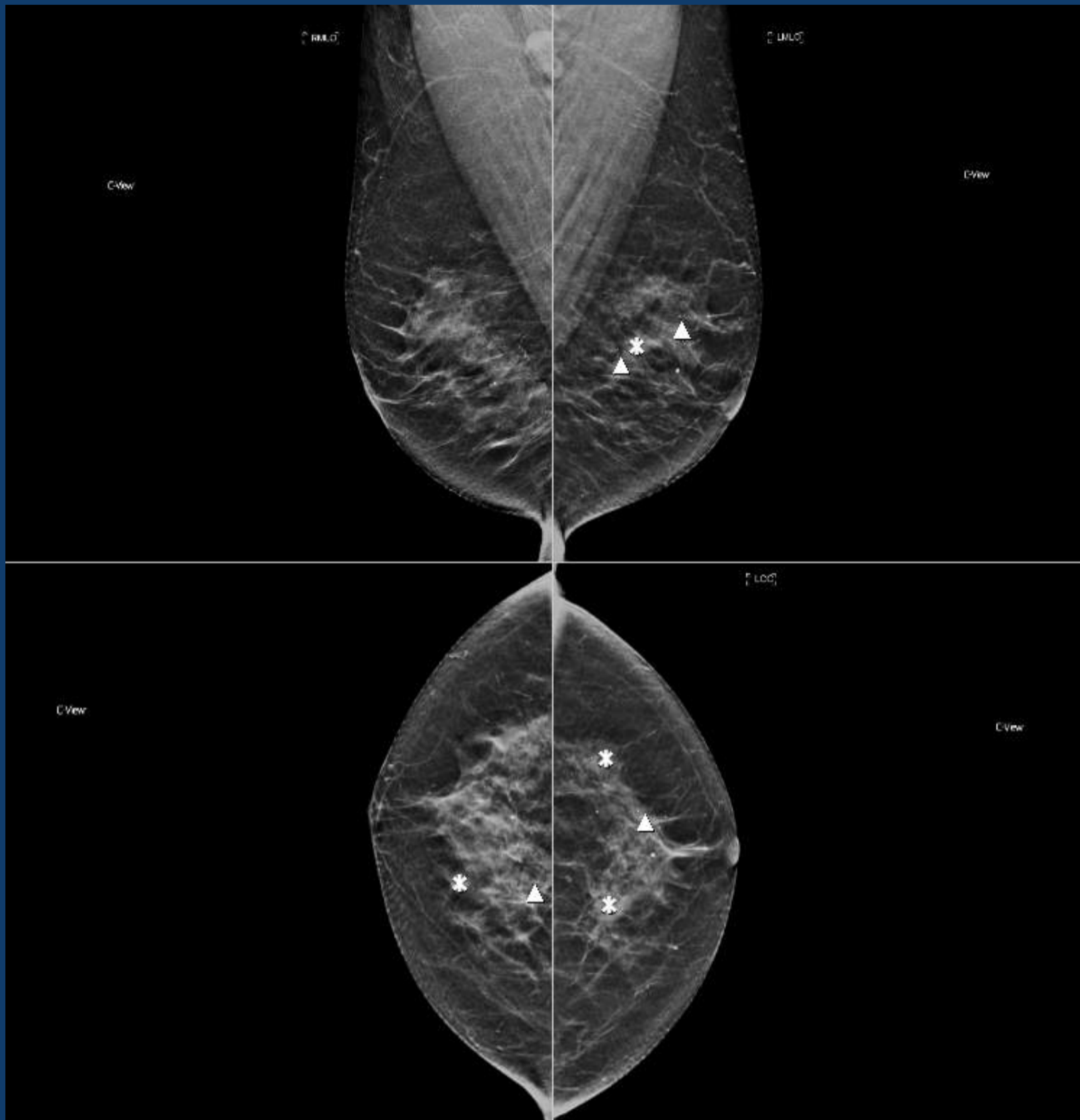
HANGING 2ND UP



Synthetic view

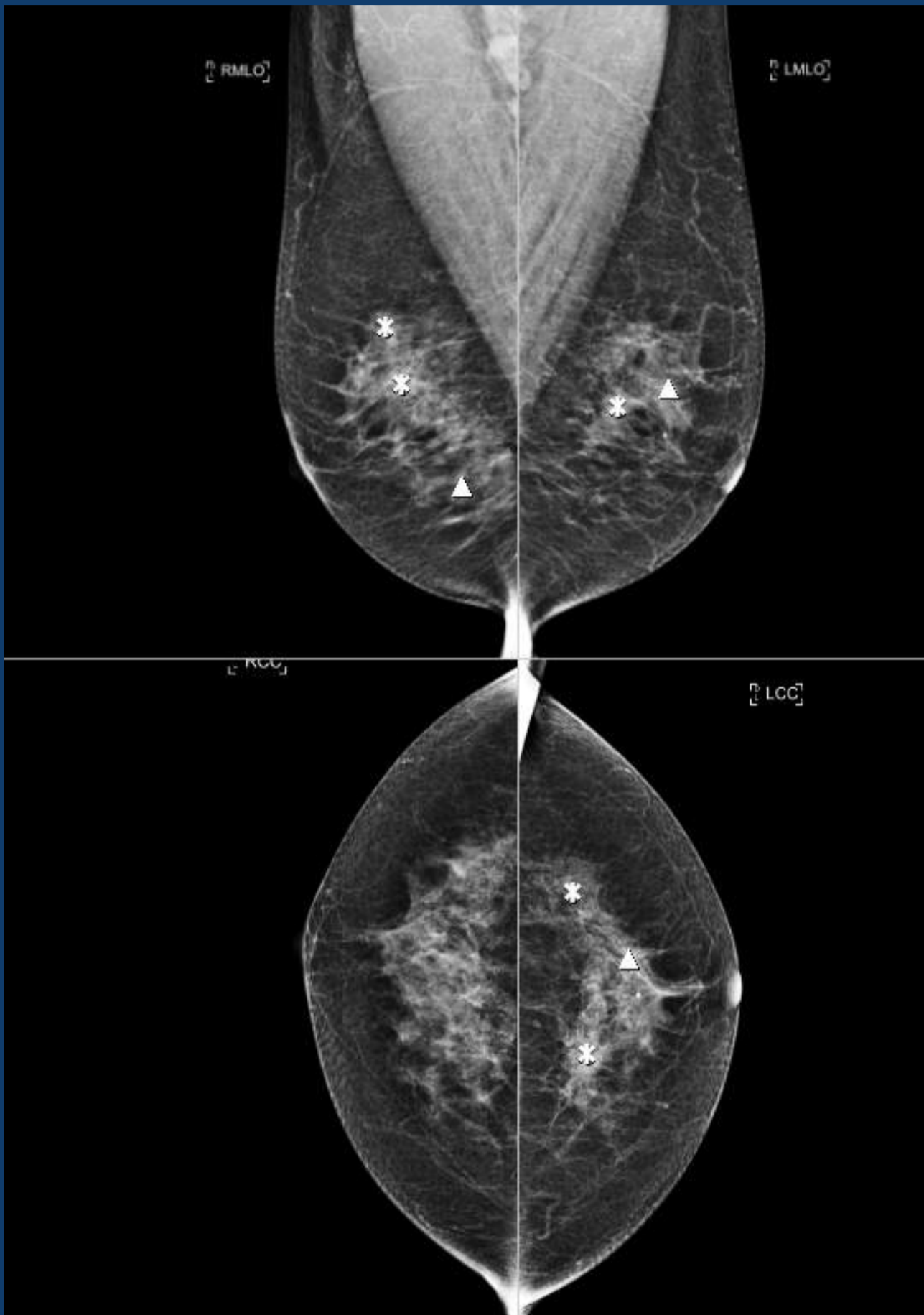
DBT

CAD (SYNTHESIZED VIEWS)



Apply CAD at end of 2D hanging and may have to go back and review an area if need be

FFDM CAD



Apply CAD at end of 2D hanging and may have to go back and review an area if need be

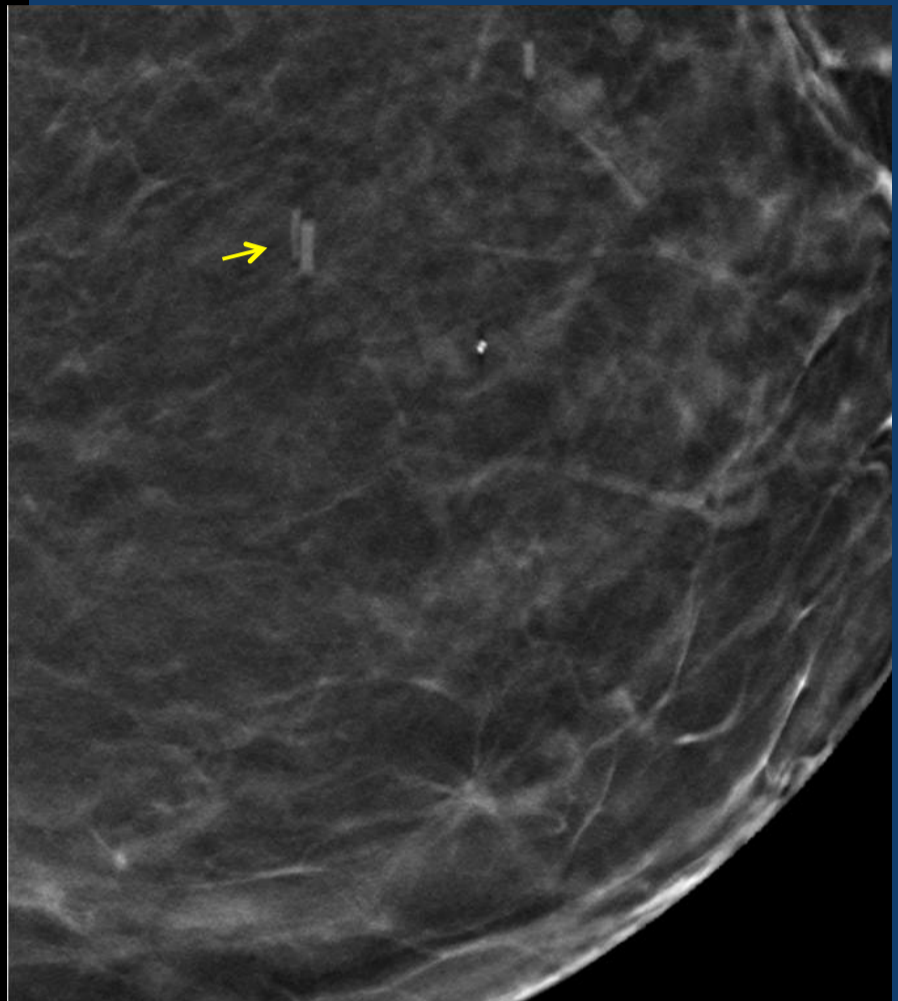
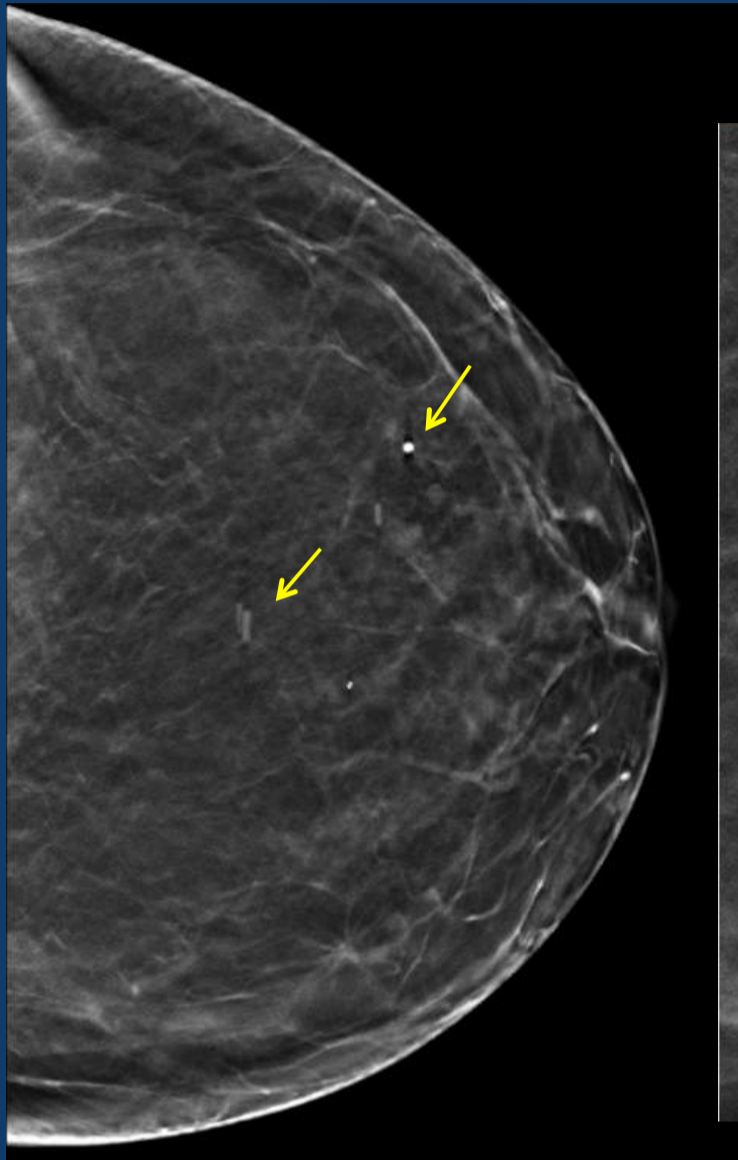
IMAGING CONSIDERATIONS

- Motion is a concern due to longer exposure times
 - Will likely occur as much as FFDM or more
 - Technologist may need to instruct the patient to stop breathing during the sweep
 - Technologists need to check at acquisition and repeat as necessary
 - Dose will increase if images are repeated

IMAGING & INTERPRETATION CONSIDERATIONS

- Image artifacts
 - Calcifications
 - Foreign objects: surgical staples and clips
- Biopsy of DBT only/predominant found lesions

IMAGING & INTERPRETATION CONSIDERATIONS



DBT IMPLEMENTATION

- Exciting new technology with smooth transition
 - Required training for radiologists
 - Learning curve for the radiologist
 - Longer reading times
 - Training needed to accommodate learning curve, reading time, comparison with priors, hanging protocols
-

REFERENCES

- Friedewald S, et al. Breast Cancer Screening Using Tomosynthesis in a Combination with Digital Mammography. JAMA. 2014. 311(24);2499-2507.
- Skaane P, et al. Comparison of Digital Mammography alone and Digital Mammography Plus Tomosynthesis in a Population-based Screening Program. Radiology. 2013. 267(1);47-56
- Brandt KR, et al. Can Digital Breast Tomosynthesis Replace Conventional Diagnostic Mammography Views for Screening Recalls Without Calcifications? A Comparison study in a Simulated Clinical Setting. AJR 2013; 200: 291-298.
- Rose SL, et al. Implementation of Breast Tomosynthesis in a Routine Screening Practice: An Observational Study. AJR 2013; 200:1401-1408
- Skaane P, et al. Trends in Time to Interpretation of Tomosynthesis Based Screening Examinations with Increasing Experience. Presented RSNA 2013
- Schrading S, et al. Digital Breast Tomosynthesis-guided Vacuum-assisted Breast Biopsy: Initial Experiences and Comparison with Prone Stereotactic Vacuum-assisted Biopsy. Radiology 2014
- Skaane P, et al. Two-View Digital Breast Tomosynthesis Screening with Synthetically Reconstructed Projection Images: Comparison with Digital Breast Tomosynthesis with Full-Field Digital Mammographic Images. Radiology 2014 271(3);655-663