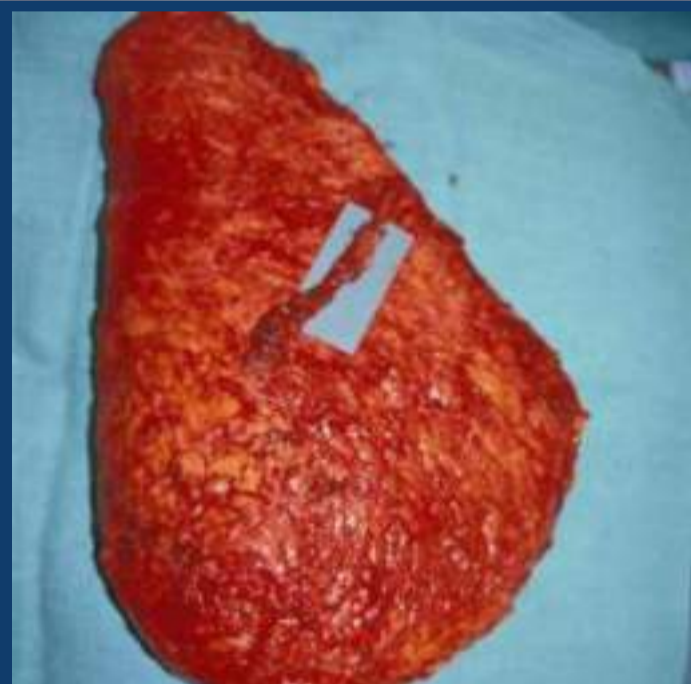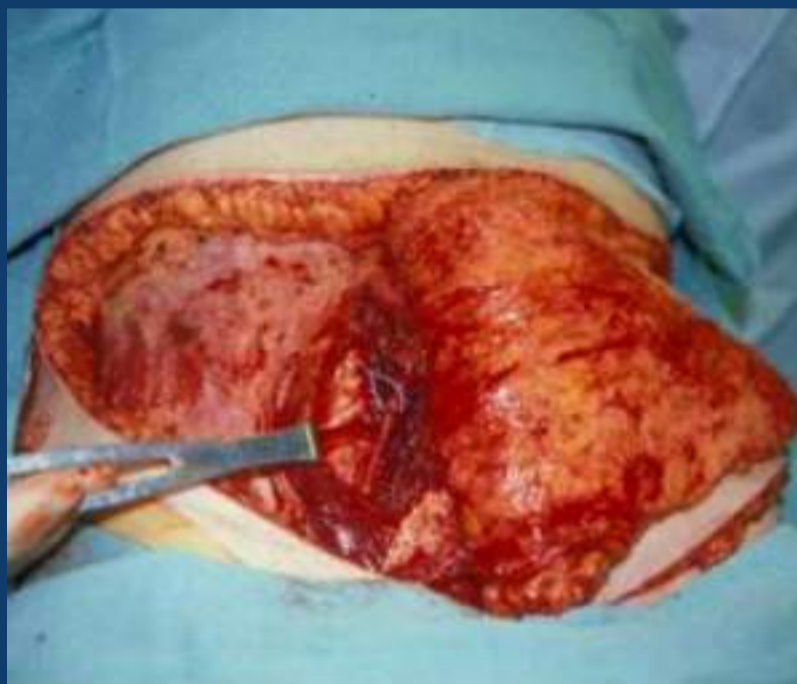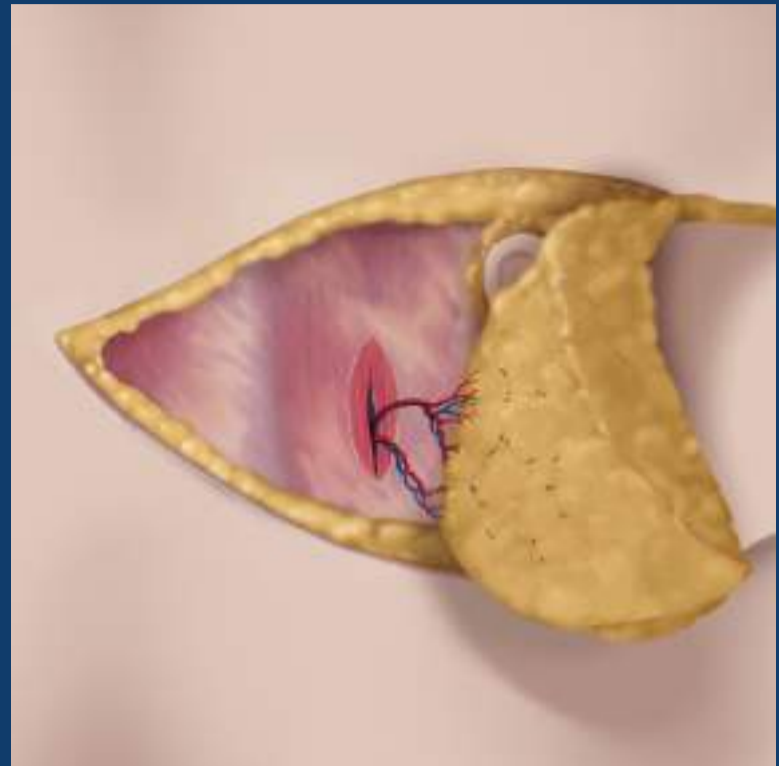
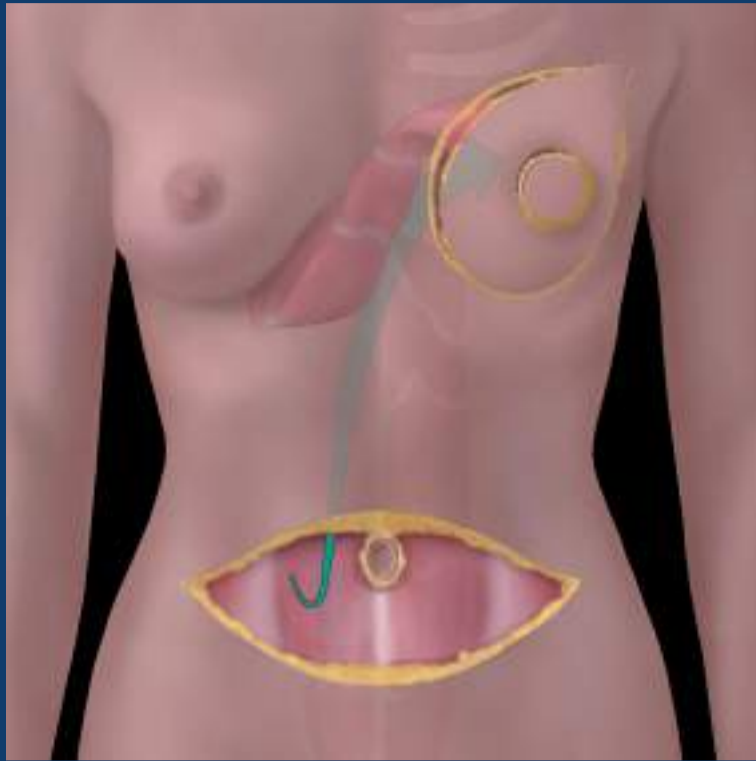


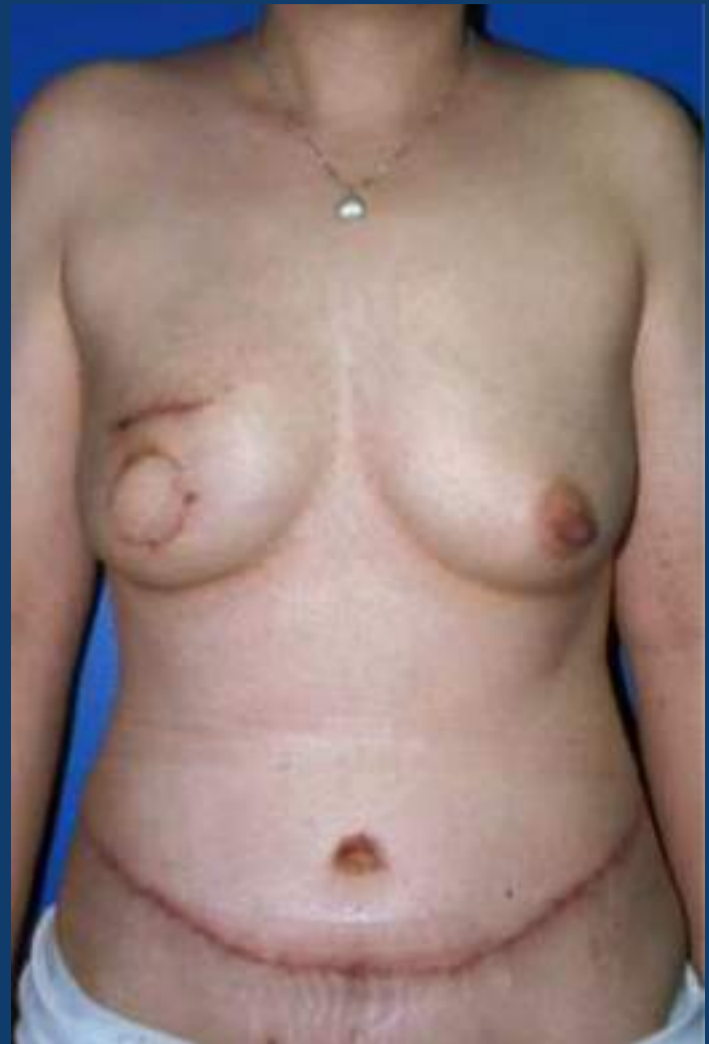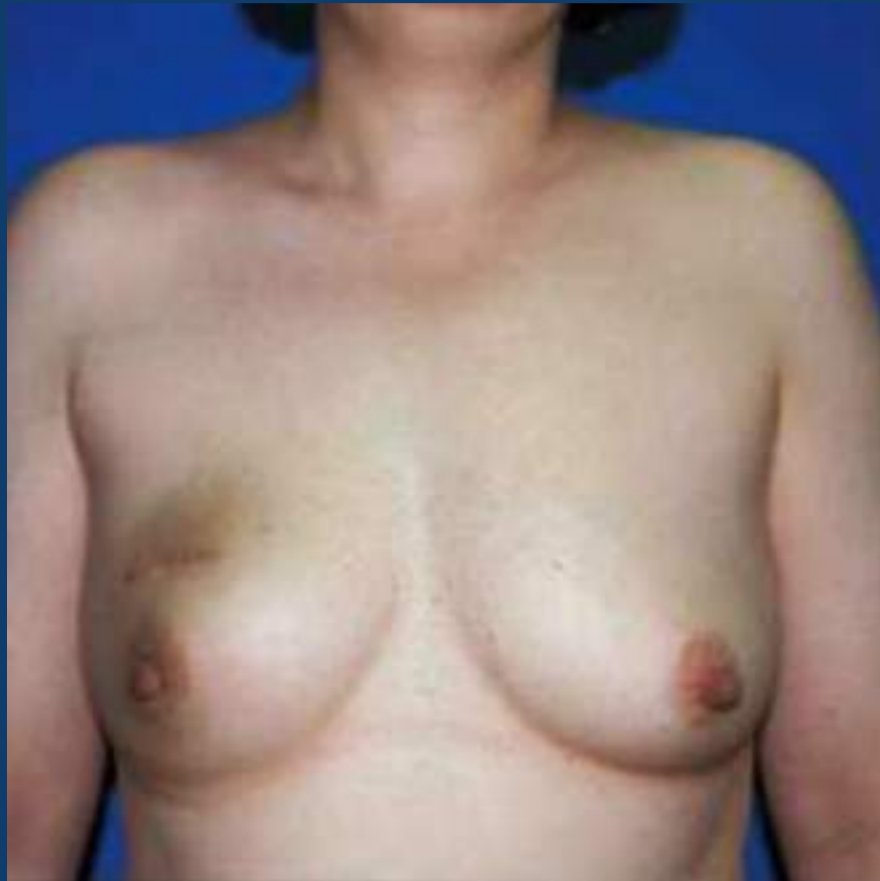Autologous breast tissue reconstruction



Courtesy Mark Clemens Warren, MD

Autologous breast tissue reconstruction



Clinical Issues

- 4-11% TRAM flap patients develop recurrence
 - Appears similar to primary breast carcinoma
- Possible ↑ risk of recurrence with immediate flap Sx
 - Positive margins more common
- Reconstruction does not compromise adjuvant CT
 - XRT not contraindicated
- Fat necrosis can mimic cancer recurrence:
 - Biopsy warranted if suspicious; obtain surgical history prior to biopsy to avoid traversing flap vascular supply
- Mammographic screening of neobreast controversial